

5

A system of design

J. C. Davenport,¹ R. M. Basker,² J. R. Heath,³ J. P. Ralph,⁴ and P-O. Glantz,⁵

This article describes a method of building RPD components into an effective design and indicates how the details of the design can be communicated clearly to the dental technician.

In this part, we will discuss

- Design sequence
- Design examples
- Reviewing the designs
- Design prescription

It will already be appreciated that an RPD is the sum of a number of components. In this part of the series we describe a method of building these components into a design and emphasize the importance of clearly detailing the design to the dental technician.

It must of course be remembered that the design sequence is but one stage of the overall treatment plan for a partially edentulous patient and is undertaken after completing the all-important stages of surveying the cast and selecting a path of insertion.

The following two examples illustrate how to apply the basic principles of design using the following sequence:

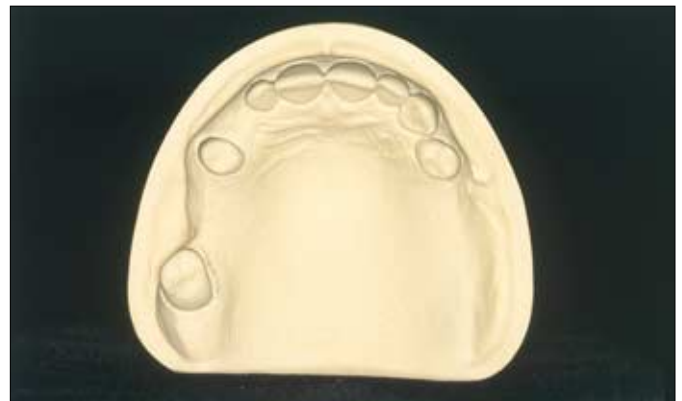1. Saddles.
2. Support.
3. Retention.
4. Bracing and reciprocation.
5. Connector.
6. Indirect retention.
7. Review of completed design.

To help with identification, the various RPD components are illustrated in different colours.

Example 1

Fig. 1 — Example 1

This maxillary arch has two bounded edentulous areas on the right side and a distal extension edentulous area on the left. The teeth have small crowns. Tooth UL4 (24) is rotated disto-buccally.



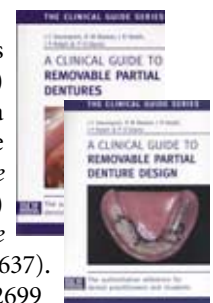¹Emeritus Professor, University of Birmingham, UK; ²Professor of Dental Prosthetics, University of Leeds and Consultant in Restorative Dentistry, Leeds Teaching Hospitals NHS Trust, Leeds, UK; ³Honorary Research Fellow, University of Manchester (Formerly Senior Lecturer in Restorative Dentistry, University of Manchester) and Consultant in Restorative Dentistry, Central Manchester Healthcare Trust, Manchester, UK; ⁴Consultant in Restorative Dentistry, Leeds Teaching Hospitals NHS Trust and Senior Clinical Lecturer, University of Leeds and Honorary Visiting Professor, Centre for Dental Services Studies, University of York, York, UK; ⁵Professor of Prosthetic Dentistry, Consultant in Prosthetic Dentistry, Faculty of Odontology, University of Malmo, Sweden
*Correspondence to: 5 Victoria Road, Harborne, Birmingham B17 0AG
email: john.davenport@btclick.com

REFEREED PAPER

© British Dental Journal 2000; 189: 586-590

New publications:

All the parts which comprise this series (which will be published in the BDJ) have been included (together with a number of unpublished parts) in the books *A Clinical Guide to Removable Partial Dentures* (ISBN 0-904588-599) and *A Clinical Guide to Removable Partial Denture Design* (ISBN 0-904588-637). Available from Macmillan on 01256 302699

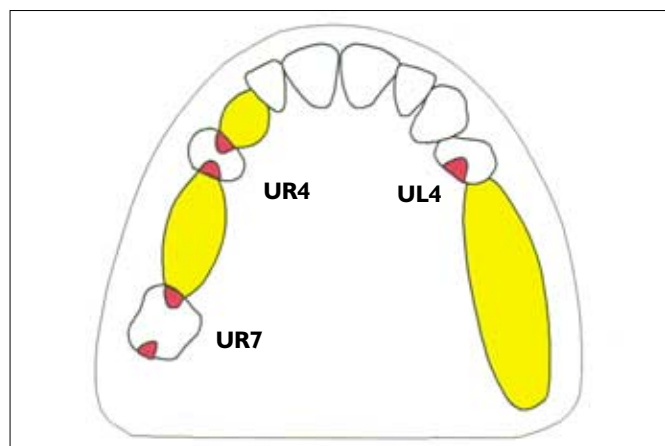


Saddles (yellow) and support (red)

Fig. 2 — Saddles and support

There is no requirement for a labial flange at UR3(13). It has been decided to use a 'closed' design for all three saddles as the short clinical crowns offer limited prospects for clasp retention. The saddle must be fully extended in the distal extension edentulous area. Spaced meshwork will be requested for the two posterior saddles to enable them to be relined when required.

Tooth support is to be gained on UR7 (17), UR4 (14) and UL4 (24). Because UL4 (24) is rotated, a mesial rest would be very visible and unsightly. The occlusal rest is therefore placed on the distal aspect of the tooth. This conflicts with advice given elsewhere in our BDJ publication *A Clinical Guide to Removable Partial Denture Design* to support a distal extension saddle with a mesial rest. However, as the load from a maxillary RPD can be distributed widely over the hard palate the problems associated with differential support are not so marked here as they are in the mandible. Rest seat preparation is planned for the three teeth. As it is not possible to make this denture totally tooth-supported, additional support must be gained from palatal coverage.

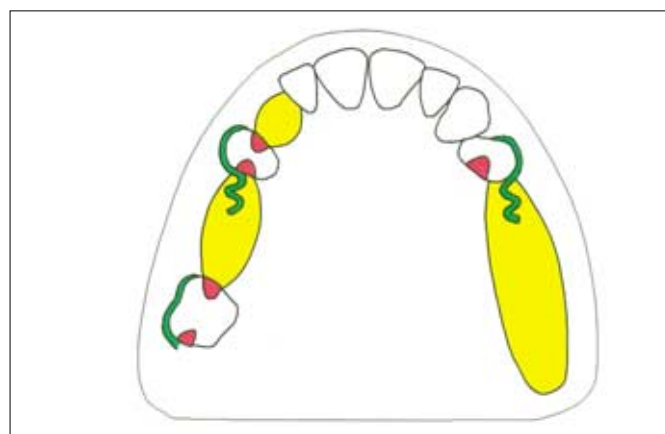


Retention (green)

Fig. 3 — Retention

It is practicable to obtain clasp retention from only three teeth (UR7 (17), UR4 (14) and UL4 (24)). Thus supplementary retention must be obtained by wide palatal coverage, full extension of the denture base into the left buccal sulcus and around the left tuberosity, and by contact with the guide surfaces which will be prepared on the abutment teeth.

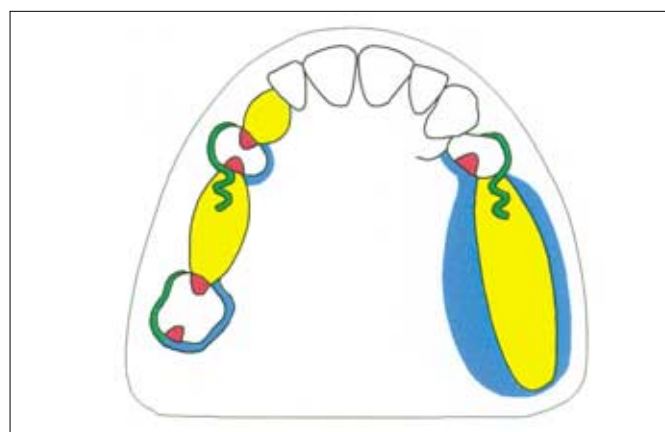
As most of the undercut on UR7 (17) is situated on its mesiobuccal aspect, a 'ring' clasp is a suitable design. It is not possible to use a gingivally approaching clasp on UR4 (14) because of a bony undercut in the buccal sulcus. As an occlusally approaching clasp is the only reasonable alternative, wrought gold wire has been chosen because it possesses sufficient flexibility for the short clasp arm to function efficiently. As a prominent fraenum precludes a gingivally approaching clasp on UL4 (24), a wrought gold occlusally approaching clasp is to be used here also.



Bracing and reciprocation (blue)

Fig. 4 — Bracing and reciprocation

It has been decided to obtain bracing from the rigid palatal arm of the 'ring' clasp on UR7 (17), by contacting the palatal aspects of UR4 (14) and UL4 (24) with the connector and by full extension of the distal extension saddle. In this instance the bracing components on the teeth will also provide reciprocation to the retentive arms on the premolars. Retention will also be assisted by the buccal placement of all retentive arms, thus providing cross-arch reciprocation.

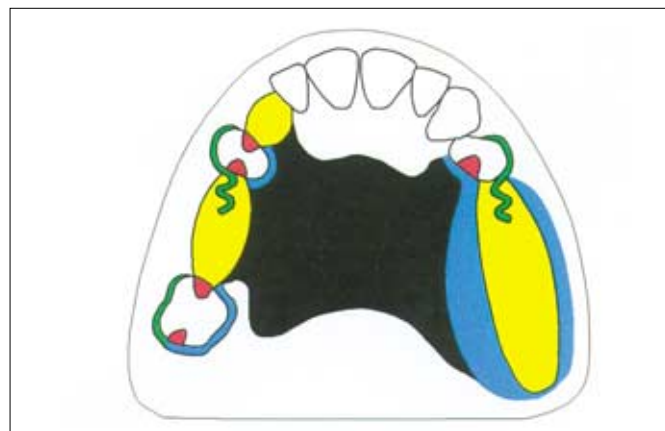


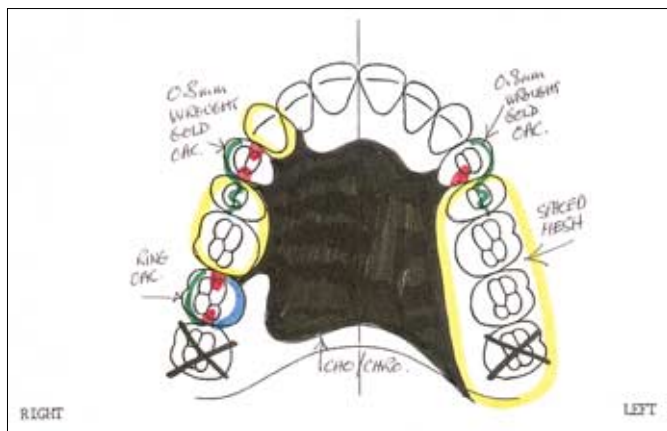
Connector (black) and indirect retention

Fig. 5 — Connector and indirect retention

For the reasons given already, wide palatal coverage by the connector is needed. However, it is possible to keep the anterior border of the palatal plate away from the anterior teeth and from the sensitive area around the incisive papilla to promote hygiene and tolerance to the framework.

It is necessary to plan for indirect retention to prevent the distal extension saddle from moving occlusally. The major clasp axis is sited through UR7 (17) and UL4 (24). The mesial occlusal rest on UR4 (14) will be the indirect retainer to resist the displacing force.





Design prescription

Fig. 6 — Design prescription

A provisional RPD design, produced at the initial treatment planning stage, should be drawn on a proforma to provide easy reference while any other restorative treatment is being carried out. Once this treatment has been completed the provisional design should be reviewed and updated in the light of any changes in the treatment plan that proved to be necessary.

Having completed the design it is important to review the result and to check that the design satisfies the four principles that have been shown to promote continued oral health (*Part 2 of this series*):

- Effective support.
- Clearance of gingival margins.
- Simplicity.
- Rigid connector.



Fig. 7 — Design prescription

The confirmed design should also be drawn on the surveyed master cast. The use of a different coloured lead to that used in the survey will improve clarity.

The resulting definitive RPD design prescription is given to the dental technician with the final impression. The prescription must include details of the materials to be used. In this case the dental technician will be asked to construct a cobalt chromium casting with the retentive clasps on UR4 (14) and UL4 (24) being made from 0.8 mm wrought gold wire.

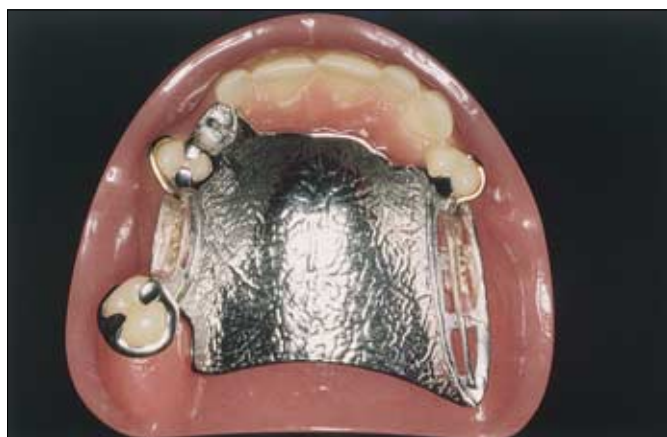
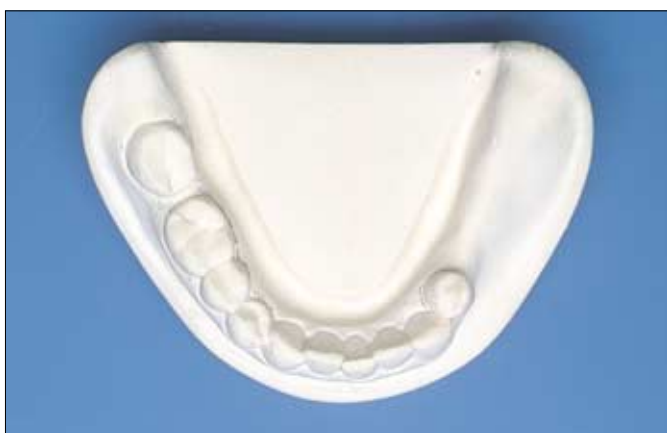
Fig. 8 — The completed framework

Careful planning and clear prescription result in the required metal framework.



Example 2

Fig. 9 — Example 2

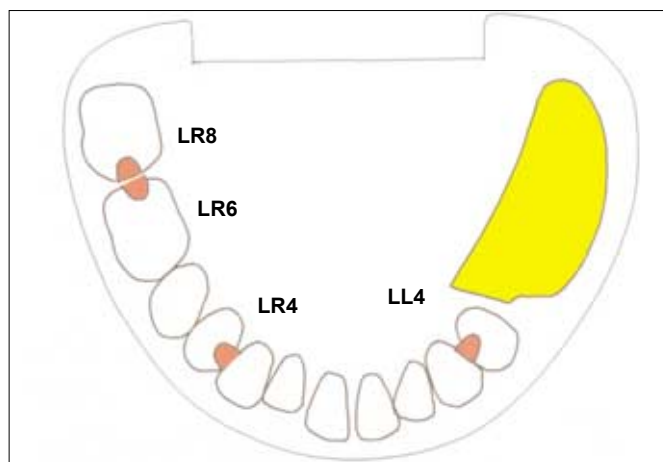
This mandibular arch has a unilateral distal extension edentulous area. A gap exists between LR6 (46) and the mesially tilted LR8 (48).

Saddles (yellow) and support (red)

Fig. 10 — Saddles and support

A spaced retaining meshwork will be required to enable the saddle to be relined following alveolar resorption. A narrow occlusal table will be used to reduce the load falling on the tissues of the edentulous area. A closed design will be used to provide reciprocation on the distal surface of LL4 (34).

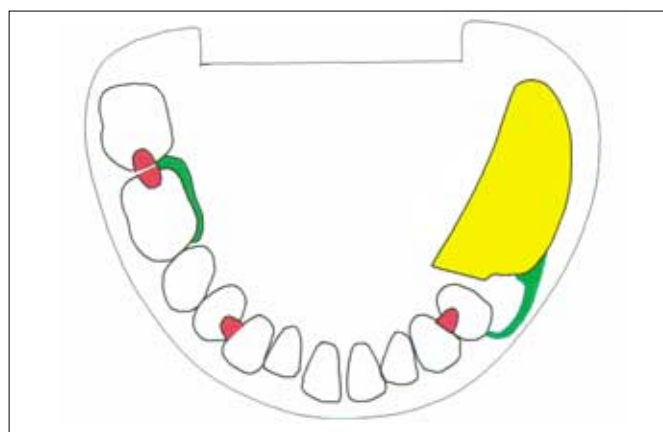
Tooth support for the saddle will be gained from a mesial occlusal rest on LL4 (34). The greatest possible mucosa support for the saddle is achieved by extending the denture base onto the pear-shaped pad and to the full functional depth of the lingual and buccal sulci. On the right side of the arch it is important to spread the support so that a stable prosthesis can be produced, thus rests have been placed on LR4 (44), LR6 (46) and LR8 (48). The occlusal rests on the molars bridge the gap between the two teeth. Rest seat preparations will be carried out.



Retention (green)

Fig. 11 — Retention

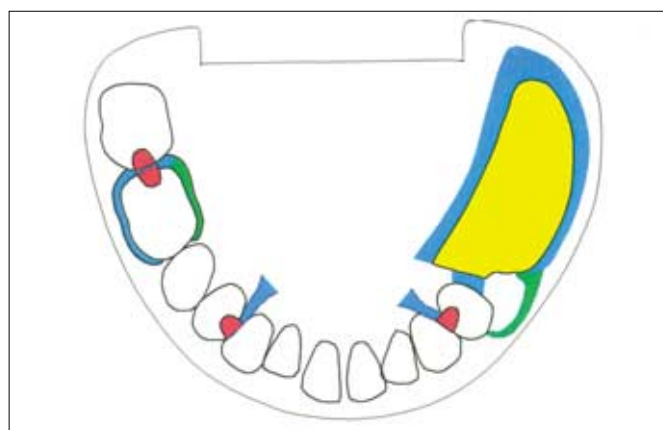
The distal extension saddle will be carefully shaped to enable the oral musculature to act against the polished surface to control the denture. Suitable undercut and sulcus shapes allow a gingivally approaching clasp to be used on LL4 (34). This clasp will be one of the components for the RPI system and the tooth will be prepared accordingly. On LR6 (46) the usable undercut is on the mesiolingual aspect of the tooth and will be engaged by an occlusally approaching clasp.



Bracing and reciprocation (blue)

Fig. 12 — Bracing and reciprocation

Lateral forces will be transmitted through the minor connectors, through the buccal bracing arm on LR6 (46) and to the tissues of the edentulous area through the fully extended flanges. Guide surfaces will be prepared on LL4 (34) and LR6 (46) to provide reciprocation for the retentive clasps.

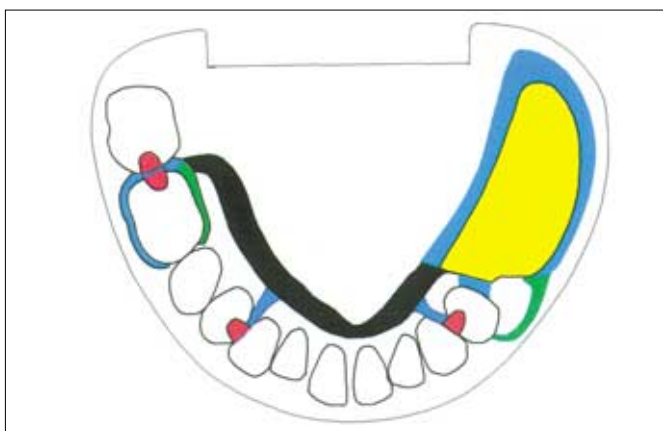


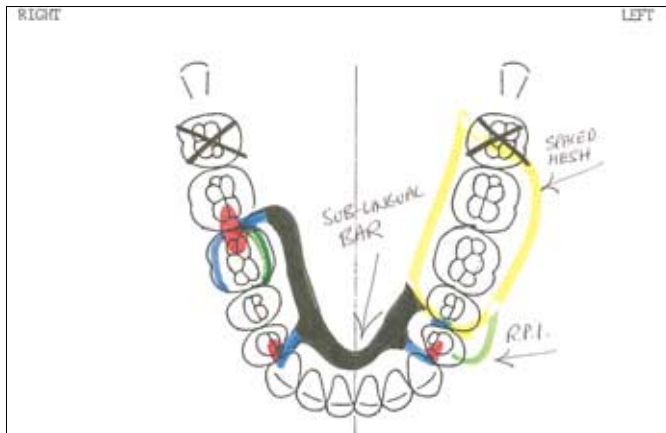
Connector (black) and indirect retention

Fig. 13 — Connector and indirect retention

There is sufficient depth in the lingual sulcus for a sublingual bar. This connector will be rigid and will avoid coverage of the gingival margins. The three minor connectors will be placed as unobtrusively as possible in the embrasures between the teeth so that the framework is well tolerated by the patient.

The occlusal rest on LR4 (44) will provide effective indirect retention for the distal extension saddle because it is positioned well in front of the clasp axis passing through LL4 (34) and LR6 (46).





Design prescription

Fig. 14 — Design prescription

The design is reviewed as described in Fig. 6 and then given to the dental technician on a clearly labelled proforma as described for Example 1.

In this instance the whole casting will be constructed in cobalt chromium alloy.



Fig. 15 — Design prescription

The shape of the lingual sulcus, faithfully recorded on the cast, dictates the shape and location of the sublingual bar. Nevertheless, it is wise to draw the outline of the connector on the cast to avoid any misunderstanding about its required position.

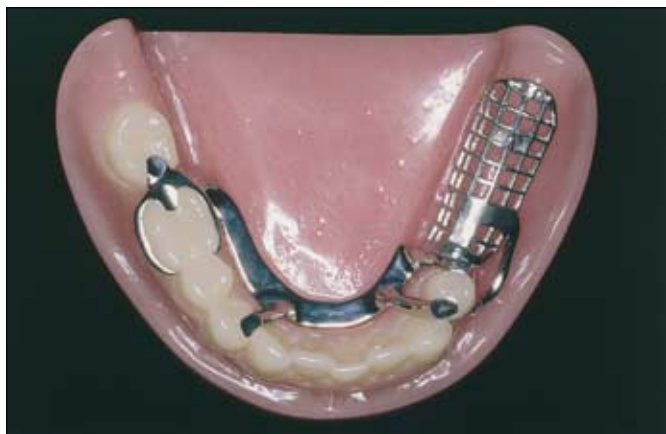


Fig. 16 — The completed framework

Careful planning and clear prescription again result in the required metal framework.